



PATIENT

Klaus Hartinger

SPECIES

Canine

BREED

Boxer

SEX

Male Neutered

AGE

10 years

WEIGHT

72.3lbs

INTERPRETED BY

Maggie Machen Lamy,
DVM, DACVIM
(Cardiology)

IMAGING PERFORMED BY

Dana Alterman,
RDCS, LVT

HOSPITAL NAME

Eubank Animal Clinic

REFERRING VET

Dr. Gardner

INVOICE

30672

DATE

5/9/23

PRESENTING CLINICAL SIGNS

History: Grade 1-2/6 left sided murmur. Arrhythmia. Has been on grain-free diet in past, currently on Science Diet Senior. Assess prior to anesthesia.

-Abnormal PE/Chem/CBC/UA Results: Hepatopathy - ALT 207, ALK - 1549. Possible HAC.

ELECTROCARDIOGRAPHIC FINDINGS

A six lead ECG is available at 25mm/s; 10mm/mV. The average heart rate is 110bpm (range 94-136bpm). The rhythm is sinus in origin, with a p for every QRS complex and vice versa. The P wave morphology is positive with a normal dimension. Normal PR. The QRS morphology is positive with normal dimension. MEA is normal. Isolated VPCs are seen throughout; singles only and monomorphic. LBBB morphology indicative of an RV origin. No supraventricular premature beats, pauses or other dysrhythmias observed.

ECG diagnosis: Normal sinus rhythm with frequent isolated VPCs.

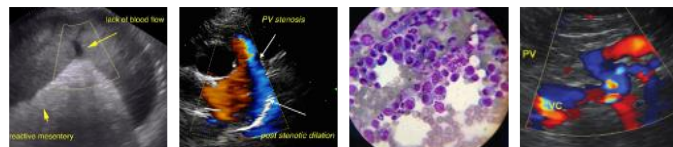
ECHOCARDIOGRAM FINDINGS

2D, m-mode, color flow and doppler imaging is available. Mild diffuse thickening of mitral valve leaflets with no prolapse into the left atrial lumen. No mitral regurgitation with no left atrial dilation. Normal LV diameter with adequate myocardial function. The tricuspid valve appears normal with no tricuspid regurgitation. Normal right atrial and ventricular diameter and morphology indicating no overt evidence of pulmonary arterial hypertension. The pulmonic and aortic valves are normal in morphology and mobility. Normal pulmonic and aortic outflow velocities with laminar flow. No obvious aortic or pulmonic insufficiency. No pericardial or pleural effusion noted. No obvious cardiac masses.

CARDIAC CHART

CANINE CARDIAC PARAMETERS	MR VMAX (m/s)	TR VMAX (m/s)	LA/AO (Boon method)	LA/AO (Heart Base; Swe)	FS (%)	EF (%)	EPSS (cm)
NORMAL PARAMETER	4.5-5.5	<2.7	1.3	<1.6	28-40	40-100	<0.6
PATIENT	NA	NA	1.4	1.5	40	71	NM
CANINE CARDIAC PARAMETERS	HR (BPM)	AV VMAX (m/s)	PV MAX (m/s)	BODY WEIGHT (kg)	LA 2D short axis Base view (cm)	LVIDd Avg; 2D and m-mode short axis (cm)	LVIDs Avg; 2D and m-mode short axis (cm)
NORMAL PARAMETER	50-100	0.7-1.7	0.7-1.6	BELOW	BELOW	BELOW	BELOW
PATIENT	NM	0.8	0.93	32.8	3.0	4.3	2.6
*Normal chamber parameters expressed as a mean value (SD)				3	1.27 (5.3)	2.46 (2.46)	1.36 (5.5)
BODY WEIGHT DEPENDENT PARAMETERS				5	1.40 (4.5)	2.74 (5.2)	1.60 (4.7)
*Note: All measurements based upon multi-modal images and methods. An average value is reported.				10	1.50 (3.8)	3.27 (3.5)	2.06 (3.1)
				15	1.83 (2.0)	3.71 (2.4)	2.43 (2.1)
				20	2.02 (1.9)	4.14 (2.2)	2.80 (2.0)
				25	2.18 (2.4)	4.48 (2.9)	3.10 (2.5)
				30	2.33 (3.3)	4.83 (3.9)	3.39 (3.4)
				35	2.48 (4.3)	5.17 (5.0)	3.69 (4.5)
				40	2.62 (5.2)	5.48 (6.1)	3.96 (5.4)
				50	2.88 (7.1)	6.07 (8.3)	4.46 (7.4)

Adapted from June Boon, Veterinary Echocardiography, 1998
Rishniw M and Hollis NE, J Vet Intern Med 2000; 14:429-435
Hansson et al, Vet Rad and Ultrasound 2002
Bonagura et al. Echocardiography: principles of interpretation, Vet Clin North Am 15:1177, 1995



PATIENT	<u>INTERPRETATION OF THE FINDINGS & FURTHER RECOMMENDATIONS</u>
Klaus Hartinger	The cardiac structure and function are essentially normal in this patient. There is mild right heart prominence in some views; however, this is angle dependent and may be a normal variant. The left heart dimensions are normal, and the systolic function considered adequate for a large breed dog. No valvular insufficiencies were noted, and no structural issues identified. No evidence of diet-related cardiomyopathy.
SPECIES	
Canine	
BREED	Frequent ventricular premature contractions were confirmed as the cause of the noted arrhythmia. VPCs are generated from abnormal conductive or fibrotic tissue in the ventricles of the heart muscle, and even frequent single VPCs will often cause no clinical signs in dogs. When sustained however, ventricular tachycardia can lead to symptoms such as lethargy and collapse.
Boxer	
SEX	VPCs are a very non-specific finding. They can be primary in origin (such as ARVC), be secondary to significant cardiac disease (not present in this study) or be extra-cardiac in origin; i.e., due to pain, stress, inflammation, cancer, GI disease, DIC/sepsis, etc. In a 10yo Boxer, there is high suspicion for ARVC (albeit most common age of onset 6-8yo, often asymptomatic). ARVC can occur with or without systolic dysfunction and structural issues, however this should be monitored going forward for any progressive issues. It is always reasonable to rule out other differentials for VPCs (AUS, tick titers, troponin, etc.) particularly in a senior dog. Unfortunately, there is always an elevated risk for collapse and sudden death in any arrhythmic patient, and even on medications this risk unfortunately still persists. ARVC carries a HIGHLY variable prognosis, with some dogs able to remain asymptomatic for extended periods of time, and others developing exercise intolerance, syncopal episode, and refractory arrhythmias/sudden death imminently.
Male Neutered	
AGE	
10 years	
WEIGHT	
72.3lbs	
INTERPRETED BY	Anti-arrhythmic therapy may be warranted at this time. That being said, with only single VPCs, a holter monitor would be the gold standard to fully understand the extent of the arrhythmia. If declined or not possible, I would err on the side of side of caution and institute Sotalol at this time as below. Discussion with the owner is advised.
Maggie Machen Lamy, DVM, DACVIM (Cardiology)	
IMAGING PERFORMED BY	Fish oil supplementation is recommended for dogs with arrhythmias (1000mg of omega 3 and 6 once to twice daily as tolerated).
Dana Alterman, RDCS, LVT	
HOSPITAL NAME	Once the arrhythmia is controlled, anesthetic risk is considered moderate. Avoid ketamine, telazol, Dexdomitor (or other alpha-2 agonists) and acepromazine. Recommend having lidocaine CRI available for use in the event of worsening ventricular arrhythmias under anesthesia (CRI 50–75mcg/kg/min).
Eubank Animal Clinic	
REFERRING VET	Monitor at home for collapse, exercise intolerance, and/or lethargy. Anesthesia is not recommended until good arrhythmic control is achieved. Lifelong mild to moderate activity restriction is advised.
Dr. Gardner	
INVOICE	<u>PLAN</u>
30672	Consider a holter monitor as discussed. If declined, Institute sotalol 1-2mg/kg PO q12h. Recheck ECG in 1-2 weeks to assess response (goal is significant reduction in ectopy without a significant change in underlying sinus rate).
DATE	Recheck ECG and echocardiogram is recommended in 6 months to determine progression/control, sooner if any development of associated clinical signs.
5/9/23	



PATIENT

Klaus Hartinger

SPECIES

Canine

BREED

Boxer

SEX

Male Neutered

AGE

10 years

WEIGHT

72.3lbs

INTERPRETED BY

Maggie Machen Lamy,
DVM, DACVIM
(Cardiology)

IMAGING PERFORMED BY

Dana Alterman,
RDCS, LVT

HOSPITAL NAME

Eubank Animal Clinic

REFERRING VET

Dr. Gardner

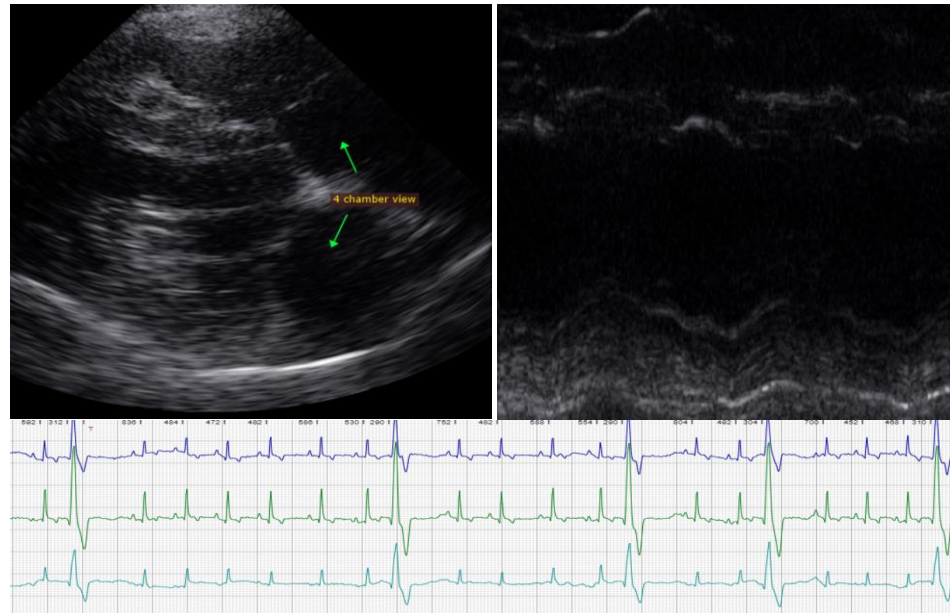
INVOICE

30672

DATE

5/9/23

IMAGES



The information and recommendations provided are based on the images presented by the referring veterinarian. No evaluation can be communicated regarding pathology that was not visible in the image/video clips provided.

Thank you for this referral. This report was generated using transcription software, and minor dictation errors may be present. If the clinical or image interpretation does not parallel your findings or if I can be of any further assistance, please contact me.

Maggie Machen Lamy, DVM
Diplomate of the American College of Veterinary Internal Medicine (Cardiology)
info@sonopath.com